



## Treatment of female stress urinary incontinence with Erbium-YAG laser in non-ablative mode



Jack I. Pardo <sup>a,\*</sup>, Vicente R. Solà <sup>b</sup>, Andrea A. Morales <sup>c</sup>

<sup>a</sup> Clínica Sara Moncada, Santiago 7700668, Chile

<sup>b</sup> Clínica Las Lilas, Santiago, Chile

<sup>c</sup> Hospital Clínico Universidad de Chile, Santiago, Chile

### ARTICLE INFO

#### Article history:

Received 4 May 2016

Accepted 28 June 2016

#### Keywords:

Stress urinary incontinence

Laser

Photothermal therapy

Vaginal prolapse

Treatment

### ABSTRACT

**Objective:** To evaluate the efficacy of laser photothermal therapy in a group of Chilean women with SUI. **Material and methods:** Longitudinal prospective study based on 42 women with mild-to-severe SUI, intervened with non ablative Er:YAG laser, between July 2014 and October 2015, in Santiago, Chile. The therapy efficacy was evaluated through the difference between every patient's scores obtained, before and after treatment, with the International Consultation on Incontinence Questionnaire – Urinary Incontinence Short Form (ICIQ-SF), at a confidence level of 95%. Also, the patient satisfaction with treatment was reported through an ordinal scale.

**Results:** ICIQ-SF median score was 11 before treatment and 3 after 6 months, with a significant difference per patient ( $p < 0.001$ ). 78.6% ( $n = 33$ ) reported improvement and 38.1% ( $n = 16$ ), a complete healing of SUI at follow up. 66.7% ( $n = 28$ ) reported high satisfaction and 81.8% ( $n = 27$ ) of sexually active women, also reported improvement of sexual gratification. Only mild pain during the procedure was reported as adverse effect.

**Conclusions:** Based on this short-term pilot study, non-ablative Er:YAG laser procedure seems to be a safe and efficacious alternative for patients with SUI. Further controlled studies will help to validate the use of non-ablative Er:YAG for treatment of SUI.

© 2016 Elsevier Ireland Ltd. All rights reserved.

### Introduction

Female stress urinary incontinence (SUI) is a highly prevalent lower urinary tract dysfunction, most commonly affecting middle-aged and elderly women [1,2]. Although the etiology of SUI is not fully understood, the risk factors for the condition include congenital factors, pregnancy, childbirth, hypoestrogenism, cognitive impairment, obesity, and advanced age [2]. Because of increased awareness about SUI, more and more physically active younger women, mostly with mild and moderate SUI, are seeking professional help for their condition.

There are many possible nonsurgical and surgical therapies for SUI; however, TVT (tension-free vaginal tape) has been considered like gold standard in SUI [3,4]. Initial therapy involves nonsurgical options such as behavioral changes in terms of diet reduction for

overweight patients, smoking cessation and pelvic floor muscle training (PFMT) [5]. Although good results can be achieved with PFMT, the long-term improvement is hard to maintain due to lack of training and poor patient persistence [6]. Drug therapy also may reduce SUI [7].

Surgical procedures are more effective for SUI than nonsurgical therapies, but are sometimes associated with adverse effects and complications, such as bleeding, bladder perforation, urethral injury, infection, groin pain and a sexual abstinence period of 6 weeks after surgery [7]. In TVT, that can be retropubic or transobturator, slings are used in order to prevent urethral descent at the time of increased intrabdominal pressure [8–10]. In recent years, less invasive single incision mini-slings have been introduced and have become very attractive; however, they have been associated with unwanted side effects as obstruction and voiding dysfunction [10,11].

Many researchers are looking for a non-invasive and safer treatment options, and recently surgical treatment is often replaced by non-invasive therapies, such as electrical stimulation,

\* Corresponding author. Tel.: +56 2 22425016; fax: +56 9 93596438.  
E-mail address: [drjackpardo@gmail.com](mailto:drjackpardo@gmail.com) (J.I. Pardo).

radiofrequency and laser photothermal therapy [6,7,12]. Studies have demonstrated remodeling and *de novo* synthesis due to photothermal effect of laser irradiation [13,14]. Since synthesis of collagen, an important component of pelvic floor supportive structures, slows down due to aging, laser-mediated heating of pelvic floor tissue could represent an effective non-surgical method for treating disorders associated to diminish pelvic floor support. In fact, Er:YAG laser therapy have been previously described as an effective and safe option for different gynecological applications, such as SUI, vaginal relaxation syndrome and vaginal atrophy [15–18].

The aim of the present study is to evaluate the short term effectiveness and safety of minimally invasive non ablative Er:YAG laser therapy for female SUI, using a validate questionnaire.

## Materials and methods

Pilot prospective study was performed between July 2014 and October 2015 in Clinica Sara Moncada, a private health center in Santiago, Chile.

The inclusion criteria for this study were a mild-to-severe SUI, to complete the interviews and to provide a written informed consent, voluntarily. The exclusion criteria were: exclusive urge incontinence, severe prolapse, pregnancy, previous surgery due to treated condition, patients with severe neurological conditions, vaginal lesions, genitourinary tract infections, abnormal vaginal bleeding, history of photosensitivity disorder or use of photosensitizing drugs and hematuria. According to these criteria, 42 female patients were included in the study.

The degree of SUI, and its impact on quality of life, was assessed using the International Consultation on Incontinence Questionnaire – Urinary Incontinence Short Form (ICIQ-UI SF) [23], applied in person by a unique medical doctor. This questionnaire has been validated in Spanish [20] and, recently, to be used in the Chilean population [21]. The results of the ICIQ-UI SF were divided into the following four severity stages: slight (1–5), moderate (6–12), severe (13–18) and very severe (19–21) [19], as suggested by Klovning et al. [22].

To assess the improvement of SUI symptoms and the improvement of quality of life after the treatment, follow up was performed at 3–6 months using ICIQ-SF questionnaire, by telephone interviews performed by a non-medical assistant. We consider as an improvement of SUI, an ICIQ-SF score after treatment lower than that reported prior to treatment, without consider the change in the severity stage. The differences between both scores and severity stages per patient were tested for statistical significance with the Wilcoxon signed-rank test, at a confidence level of 95%. A possible association of improvement of SUI to age and the number of vaginal deliveries was evaluated through a multiple logistic regression model, at a confidence level of 95%.

Although it was not the main objective of this study, patient's satisfaction with the treatment and sexual life improvement were also reported, across an ordinal scale: no satisfaction, low, moderate or high satisfaction.

All information was gathered on a database, which was created and analyzed with the statistical software program Stata® 12.1, licensed for one of the author.

Ethics Committee of the Clinica Sara Moncada approved the research protocol on June 20, 2014, by resolution number 3.

All patients were treated according the three-step protocol using 2940 nm Er:YAG laser (Fotona Smooth™ XS, Fotona, Ljubljana, Slovenia) in non-ablative thermal only mode, equipment owned by one of the authors. The treatment was performed using outpatient clinical setting and no specific preparations or post treatment medications were needed. Although no regional or

general anesthesia was required, we used topic anesthesia (1% procaine, 1% benzocaine, 1% lidocaine), which was applied with a vaginal gauze impregnated 20 min prior the procedure. All the postmenopausal women with vaginal atrophy, and no hormonal replacement therapy, were treated with local estrogen (estriol) before treatment.

Regarding the treatment protocol, this includes three steps. In the first, irradiation of the whole vaginal wall was performed, using the full beam handpiece with circular adapter. Four passes were performed with fluence of 3 J/cm<sup>2</sup> rotating the speculum by 45° each pass. In the second step, the anterior vaginal wall was irradiated from the most distal point toward the introitus using patented handpiece with angular adapter, which was introduced to the vagina using specially designed speculum. Laser energy, with fluence of 6 J/cm<sup>2</sup> in burst of 4 consecutive smooth pulses at frequency of 1.6 Hz, was applied along anterior vaginal wall in 10 longitudinal passes, avoiding overlapping. In the final step, irradiation of the vestibule and the introitus was performed with straight shooting patterned handpiece and fluence of 10 J/cm<sup>2</sup>.

No anesthesia was used during the treatment. The patient discomfort and treatment tolerability as well as adverse effects were monitored during and after the treatment. No special post-operative therapy was needed; patients were only advised to avoid increased intra-abdominal pressure, as well as, sexual intercourse at least 3 days after the treatment. They were discharged immediately after the procedure.

The therapy consisted of two treatment sessions with 21–28 days interval between sessions.

## Results

All 42 patients completed the study. The age range was 30 and 79 years (median: 46.5, IQR: 17 years). The median delivery per patient was 2 (IQR: 1, range: 0–5) (Table 1). 81.1% ( $n = 86$ ) of all births ( $n = 106$ ) were vaginal deliveries.

ICIQ-SF median score before treatment was 11 (IQR: 6, range: 3–20). 9.5% ( $n = 4$ ) of all patients had a slight SUI, 47.6% ( $n = 20$ ) moderate, 40.5% ( $n = 17$ ) severe and 2.4% ( $n = 1$ ) had a very severe SUI (Fig. 1a).

Follow-up was performed at a median of 5 months (IQR: 2, range: 3–6) after treatment.

The post-operative ICIQ median score was 3 (IQR: 10, range: 0–18). The difference between the two scores per patient was significantly different and lower than zero ( $p < 0.001$ ;  $z = -5.038$ ). 26.2% ( $n = 11$ ) were considered as slight SUI, 23.8% ( $n = 10$ ) moderate and 11.9% ( $n = 5$ ) severe SUI after treatment (Fig. 1b). 38.1% ( $n = 16$ ) of all patients reported a complete healing of SUI at follow up (no SUI symptoms); among which, 18.8% ( $n = 3$ ) described a slight SUI before treatment, 37.5% ( $n = 6$ ) a moderate SUI and 37.5% ( $n = 6$ ) a severe SUI and included the woman with very severe SUI (ICIQ score 20) before treatment.

Among 42 patients, the improvement was reported in 78.6% ( $n = 33$ ), which was not related to age ( $p = 0.091$ ) or the number of vaginal deliveries ( $p = 0.550$ ) in multiple logistic regression

**Table 1**  
Patient features and ICIQ-SF score before the therapy and at follow up.

	p50 (p25–p75)	Range
Age (years)	46.5 (42–57)	30–79
Deliveries	2 (2–3)	0–5
Vaginal	2 (1–3)	0–5
Cesarean	0 (0–1)	0–2
ICIQ score before	11 (8–14)	3–20
ICIQ score after	3 (0–10)	0–18
Follow up (months)	5 (4–6)	3–6

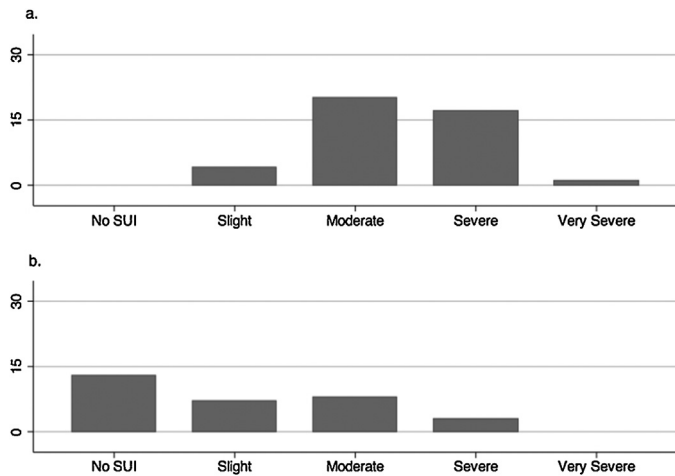


Fig. 1. SUI severity, according to ICIQ-UI SF scores: before (a) and after (b) Er:YAG laser treatment.

analysis. 38.1% ( $n = 16$ ) of patients reported an improvement of SUI in one stage, 19% ( $n = 8$ ) in two stages, 14.3% ( $n = 6$ ) in 3 stages and in one case in 4 stages (Fig. 2). The difference between stages per patient was also significantly different and lower than zero ( $p < 0.001$ ;  $z = -5.151$ ).

Although 10 patients maintained the same severity stage (Fig. 2), no improvement was reported in 7 of those patients; while, 3 cases had an improvement on ICIQ score after treatment but keeping the initial severity. In two cases a worsening of symptoms was observed, increasing from moderate to severe SUI stage in one case, after 4 months follow up.

66.7% ( $n = 28$ ) of patients reported high satisfaction with the results of the treatment (Fig. 3a), 85.7% ( $n = 36$ ) would recommend the treatment and 76.2% ( $n = 32$ ) of all patients would be willing to repeat it. Only 7.1% ( $n = 3$ ) were not satisfied with the treatment. 78.6% ( $n = 33$ ) were sexually active women. 81.8% ( $n = 27$ ) of them reported a high or moderate improvement of sexual gratification (Fig. 3b).

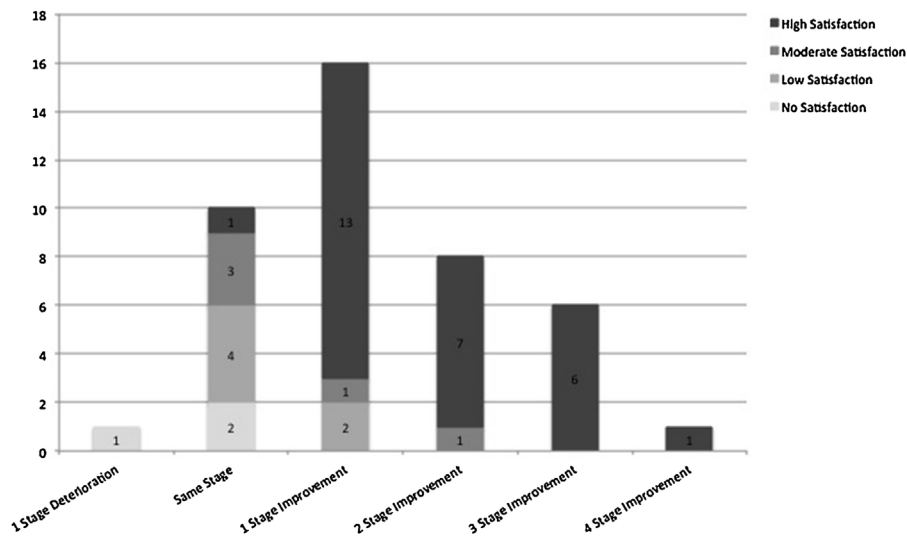


Fig. 2. Stage of improvement according to ICIQ-SF at follow up compared to patients' satisfaction with the results of the treatment.

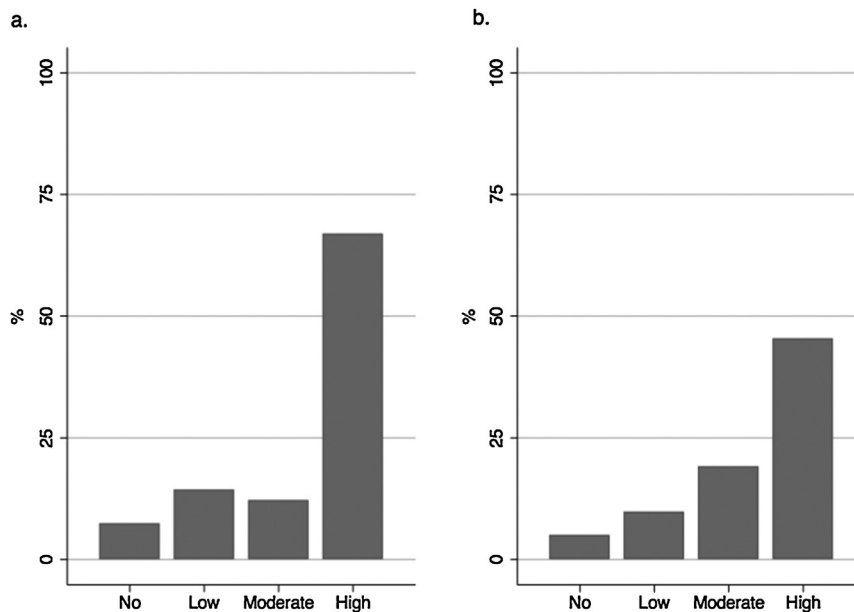


Fig. 3. Patient satisfaction after the Er:YAG laser treatment: satisfaction with the treatment (a) and sexual satisfaction (b).

The procedure was well tolerated by all patients and only mild adverse effects were reported in some patients, limited to mild pain during the treatment. No other adverse effect was reported in any patient.

## Discussion

The results of this study, using ICIQ-UI SF, indicate that Er:YAG laser therapy in non-ablative mode can effectively reduce the symptoms of SUI, even in patients with a severe stage. The improvement was evident almost immediately after treatment, reported by most patients before the second treatment session, and lasted at least 6 months. SUI treatment was well tolerated by the patients who were highly satisfied with clinical benefit of the treatment and no complications were observed. Improvement of SUI symptoms was observed also by Gambacciani et al. when treating postmenopausal women suffering from genitourinary syndrome of menopause with non-ablative Er:YAG treatment [16].

The mode of action of laser treatment for SUI is thickening and strengthening of the vaginal wall, especially anterior compartment which supports the bladder and mainly the urethra, due to remodeling and *de novo* synthesis of collagen fibers [21].

Similar mechanism of action has been also described in treatment of SUI associated with urethral hypermobility using an emitting device of radiofrequency (RF) [12,23,24]. Transurethral RF provides less invasive option for treatment of SUI compared to surgery, although anesthesia is still needed and there is still risk of post-operative pain, slight blood in the urine and urinary tract infections due to transurethral procedure [12,23,24].

Use of fractional CO<sub>2</sub> and Er:YAG laser for vaginal rejuvenation treatment, addressing also SUI symptoms, has been described, based on ablation of mucosal tissue, and although described as minimally invasive [25], a long recovery time was still needed, accompanied by bleeding, pain and burning sensation after the treatment [25]. Non ablative Er:YAG laser seems to provide a safer option, only using thermal parameters, creating a controlled temperature increase within the mucous tissue without any ablation, allowing a shorter down time and less adverse effects.

Although our study have some limitations, such as a short follow up, absence of control group and small sample size, present data obtained by ICIQ confirm that Er:YAG laser in non-ablative mode offers a new option for non-invasive treatment of stress urinary incontinence.

## Conclusions

Non ablative ER:YAG treatment seems to provide a quick and highly successful ambulatory procedure for treatment of SUI, producing significant reduction of SUI symptoms, lasting at least 6 months. Procedure is minimally invasive with no cutting, no ablation and no bleeding, virtually painless, requires no anesthesia or special pre- or post-operative preparation. Based on this short-term pilot study, non-ablative Er:YAG laser procedure seems to be a safe and efficacious alternative for patients with SUI. Future controlled studies will help to validate the use of non-ablative Er:YAG for treatment of stress urinary incontinence.

## Conflicts of interest

The authors declare no conflicts of interest of any kind. The authors would also emphasize that equipment with which all procedures were performed, is owned by one of the authors, not

existing any kind of funding for the completion of this study from the company that markets them.

## References

- [1] Abrams P, Cardozo L, Fall M, et al. The standardisation of terminology of lower urinary tract function: report from the standardisation sub-committee of the international continence society. *Am J Obstet Gynecol* 2002;187:116–26.
- [2] Luber KM. The definition, prevalence, and risk factors for stress urinary incontinence. *Rev Urol* 2004;6(Suppl. 3):S3–9.
- [3] Gustaf C. Creating a gold standard surgical procedure: the development and implementation of TVT. *Int Urogynecol J* 2015;26:467–9.
- [4] Serati M, Salvatore S, Uccella S, et al. Surgical treatment for female stress urinary incontinence: what is the gold-standard procedure? *Int Urogynecol J Pelvic Floor Dysfunct* 2009 Jun;20(6):619–21.
- [5] Jayna M, Holroyd-Leduc JM, Straus SE. Management of urinary incontinence in women: scientific review. *JAMA* 2004;291(8):986–95.
- [6] Davila GW. Nonsurgical outpatient therapies for the management of female stress urinary incontinence: long-term effectiveness and durability. *Adv Urol* 2011;2011:1–14.
- [7] Jayna M, Holroyd-Leduc JM, Straus SE. Management of urinary incontinence in women. Clinical applications. *JAMA* 2004;291(8):996–9.
- [8] Solà V, Pardo J, Ricci P, Guiloff E, Chiang H. TVT versus TVT-O for minimally invasive surgical correction of stress urinary incontinence. *Int Braz J Urol* [online] 2007;33(2):246–53.
- [9] Solà V, Ricci P, Pardo J. Malla sub-medio uretral de tercera generación: experiencia con 110 TVT-Secur. *Arch Esp Urol* 2009;62:376–86.
- [10] Pardo SJ, Solà DV, Ricci AP. Experiencia preliminar con cinta de tercera generación en el tratamiento de la incontinencia de orina de esfuerzo: Miniarc. *Rev Chil Obstet Ginecol* 2009;74:253–8.
- [11] Novara G, Galfano A, Boscolo-Berto R, et al. Complication rates of tension-free midurethral slings in the treatment of female stress urinary incontinence: a systematic review and meta-analysis of randomized controlled trials comparing tension-free midurethral tapes to other surgical procedures and different devices. *Eur Urol* 2008;53:288–308.
- [12] Crivellaro S, Smith JJ. Minimally invasive therapies for female stress urinary incontinence: the current status of bioinjectables/new devices (adjustable continence therapy, urethral submucosal collagen denaturation by radiofrequency). *ScientificWorldJournal* 2009;9:466–78.
- [13] Liu H, Dang Y, Wang Z, Chai X, Ren Q. Laser induced collagen remodeling: a comparative study in vivo on mouse model. *Lasers Surg Med* 2008;40:13–9.
- [14] Drnovsek B, Beltram M, Pizem M. Novel method for evaluation of epidermal preservation and dermal collagen remodelling following photorejuvenation of human skin. *Lasers Surg Med* 2003;32(2):115–9.
- [15] Gambacciani M, Levancini M. Short-term effect of vaginal erbium laser on the genitourinary syndrome of menopause. *Minerva Ginecol* 2015;67:97–102.
- [16] Gambacciani M, Levancini M, Cervigni M. Vaginal erbium laser: the second-generation thermotherapy for the genitourinary syndrome of menopause. *Climacteric* 2015;8(5):757–63.
- [17] Gavría J, Lanz J. Laser Vaginal Tightening (LVT) – evaluation of a novel noninvasive laser treatment for vaginal relaxation syndrome. *J Laser Heal Acad* 2012;1:59–66.
- [18] Vizintin Z, Rivera M, Fističić I, et al. Novel minimally invasive VSP Er:YAG laser treatments in gynecology. *J Laser Heal Acad* 2012;1:46–58.
- [19] Avery K, Donovan J, Peters TJ, et al. ICIQ: a brief and robust measure for evaluating the symptoms and impact of urinary incontinence. *Neurourol Urodyn* 2004;23:322–30.
- [20] España M, Rebollo P, Puig M. Validación de la versión española del International Consultation on Incontinence Questionnaire-Short Form. Un cuestionario para evaluar la incontinencia urinaria Validation of the Spanish version of the International Consultation on Incontinence Questionnaire-Short Form. A questionnaire for assessing the urinary Incontinence. *Med Clin* 2004;122:288–92.
- [21] Busquets M, Serra R. Validación del cuestionario International Consultation on Incontinence Questionnaire Short-Form (ICIQ-SF) en una población chilena usuaria del Fondo Nacional de Salud (FONASA) Validation of a Spanish version of the International Consultation on Incontinence Questionnaire Short-Form. *Rev Méd Chile* 2012;140(3):340–6.
- [22] Klovning A, Avery K, Sandvik H, Hunskaar S. Comparison of two questionnaires for assessing the severity of urinary incontinence: the ICIQ-UI SF versus the incontinence severity index. *Neurourol Urodyn* 2009;28:411–5.
- [23] Lukban JC. Transurethral radiofrequency collagen denaturation for treatment of female stress urinary incontinence: a review of the literature and clinical recommendations. *Obstet Gynecol Int* 2012;1:1–6.
- [24] Elser DM, Mitchell GK, Miklos JR, et al. Nonsurgical transurethral radiofrequency collagen denaturation: results at three years after treatment. *Adv Urol* 2011;1:1–9.
- [25] Gaspar A, Addamo G, Brandi H. Vaginal fractional CO<sub>2</sub> laser: a minimally invasive option for vaginal rejuvenation. *Am J Cosmet Surg* 2011;28:156–62.